

Versatility of Perforator Pedicled Propeller Flaps as a Reconstructive Procedure for Soft Tissue Loss

AHMED M. ZIENA, M.Sc.; AHMED A.M. KHALIL, M.D.; AHMED BAHAA EL-DIN, M.D. and ALMODDATHER M. EL-HADIDY, M.D.

The Department of Plastic & Burn Surgery Center, Faculty of Medicine, Mansoura University

ABSTRACT

In this study, the versatility of the propeller flaps for reconstruction of different soft tissue defects was evaluated to determine the reliability of this technique. Twenty seven patients were included in this study. The clinical use of these flaps were analyzed in regards to comorbidities, surface area, type of the perforators identified, angle of rotation, donor site closure, flap thinning, operative time and complication. The peroneal artery perforator (PAP) flaps and posterior tibial artery perforator (PTAP) flaps were the most frequently used flaps. The overall twenty two cases were completely survived which represents (81.7%) of all the flaps. Only three cases of complete flap loss were reported which represents a total failure rate of 11.1% and last two cases were suffered from partial flap loss. By humbling, pedicled perforator flaps appeared to be a reliable and safe procedure for the coverage of soft tissue defects.

INTRODUCTION

Reconstruction of soft tissue defects is a common challenging problem. The choice of the flap in reconstructive surgery depends on the size and depth of the defect, viability of donor flap sources appropriate tissue composition, preference of surgeons. In addition, the reconstructive operation should be performed with minimal donor site morbidity [1,2].

The term "propeller flap" was introduced in 1991 by Hyakusoku et al., [4] to describe an adipocutaneous flap, based a subcutaneous pedicle, with a skin island of a length largely exceeding its width, made of two portions (the blades of the propeller), one at either side of the pedicle. The flap was rotated 90 degrees on the central pedicle, like a propeller, to reconstruct burn scar contractions at the elbow and axilla.

Subsequently, Hallock [7] used the term propeller to define a fasciocutaneous flap that he raised

over the adductor compartment of the posterior thigh, but it was based on a skeletonized perforating vessel and the skin island was rotated 180 degrees. So, a part of the flap (the larger blade) was used to resurface the defect and the other part of the flap (the minor blade) was positioned over the donor site of the larger blade facilitating its direct closure Teo, [9] greatly contributed to the definition and to the details of the surgical technique of perforator based propeller flaps.

The advisory panel of the first Tokyo meeting on perforator and propeller flaps, 2009, defined propeller flaps as "island flap that reaches the recipient site through an axial rotation. "every skin island flap can become a propeller flap. However, island flaps that reach the recipient site through an advancement movement and flaps that move through a rotation but are not completely islanded are excluded from this definition [2].

Three types of propeller flaps, Subcutaneous pedicled propeller flap, the flap is based on a random subcutaneous pedicle. The perforators included in the pedicle are not visualized or isolated. Perforator pedicled propeller flap, the fusion of the propeller concept with the perforator flap concept led to a propeller flap nourished by a perforating vessel. This is the type of propeller flap that allows the greatest degree of rotation and it is the most commonly used. Supercharged propeller flap, if a long propeller flap is needed and the isolated perforator vessel is not providing a sufficient arterial inflow or a sufficient venous outflow, an extra pedicle can be added. A vein of the flap or an extra artery can be microsurgically anastomosed to a second pedicle of the flap [2,8].

Propeller flaps have added to the armamentarium of reconstructive microsurgery [3,4]. These

pedicled perforator flaps are successfully used for soft tissue coverage in numerous regions of the body, often obviating the need for free-tissue transfer. The vascular pedicle is twisted intentionally up to 180 degrees, which contradicts common surgical thinking [5,6].

In this study, the procedures and outcomes of all cases were reviewed and analyzed to study the versatility of the perforator pedicled propeller flaps for reconstruction of different soft tissue defects.

PATIENTS AND METHODS

General information:

Twenty seven cases (23 males and 4 females) of soft tissue loss due to any cause were included in this study. All patients were managed by propeller flaps at plastic and reconstructive surgery department, Mansoura University, Egypt from November 2012 to December 2014. Inclusion criteria were included posttraumatic wounds, infective wounds, burn contractures, pressure sores and wounds with previous graft or flap failure. Patients with life threatening injuries and those with premorbid illness (such as, heart diseases, atherosclerosis, recent stroke and/or myocardial infarction, systemic infection and peripheral vascular diseases) were excluded to avoid their possible effects of the viability of the flap.

All patients were assessed preoperatively through history that include; age, sex, size and depth of the defect and donor site condition. The routine preoperative clinical assessment, laboratory investigations to evaluate the fitness condition of the patients were done to all patients. Preoperative photos and informed consent were obtained from all patients.

Surgical technique:

Flap marking:

The patients were submitted to a preoperative mapping study with A handheld Doppler ultrasound scanner (HAYASHI DENKI CO, Japan) connected to a 5MHz vascular probe (VP5) was used to identify the most closest promising perforator vessels to the defect. Once perforating vessel was identified, there were outlined with a marker pen. Based on the previous mapping, a flap is marked around the perforator with the best pulse and location and the donor areas of the flap was designed as follows:

- 1- The distance between the perforator and the distal edge of the defect is measured (Fig. 1). This value is then transposed proximally, again measured from the perforator and this forms the proximal part of the flap which will cover the defect (major paddle $a = b + c$).
- 2- The width of the flap is equal to the width of the defect. This value is then used to determine the proximal flap width. The flap made of two paddles, one larger away from the defect and one smaller close to the defect, separated by the nourishing perforating vessel that corresponds to the pivot point.

Surgical procedure:

Fourteen patients were received spinal anesthesia and thirteen patients were received general anesthesia. A tourniquet was used in extremities without exsanguination to facilitate the dissection. The wound will be debrided and the other vital structures repaired as necessary. Exploratory incision with subfascial dissection was done to reach the preoperatively determined position of the perforator vessel and to notice its direction (Fig. 2). The perforating vessel pedicle was completely naked and freeing by completely removed the soft tissue fascia that surrounding it.

Then the flap was readjusted according to perforator position, defect size and axis of rotation. Pedicle should be cleared for all muscular side branches for at least 2cm around the flap. The perforator was isolated under loupe magnification. When the tourniquet was used, release and wait 10-15 minutes, before the flap was rotated around the defect to allow it to perfuse and to allow the spasm of the vessels to relax. Donor defect was covered with the same flap and grafting is done on the remaining area or primary closure. A drain was placed under the flap then the flap was sutured in the place and the wound was dressed.

Postoperative management:

The flap was monitored every day for seven days, as well as clinical observation by inspection of the skin color, temperature, capillary refill, pinprick test and hand held Doppler to detect any changes of the viability. Enoxaparin sodium in dose 40mg was given once daily for three days postoperative. Aspirin, 75mg, tablets were used 3 times daily during the first week, then once daily during second week. Any early or late postoperative complications will be detected and managed accordingly. All Patients will be followed-up for 4 to 6 months.

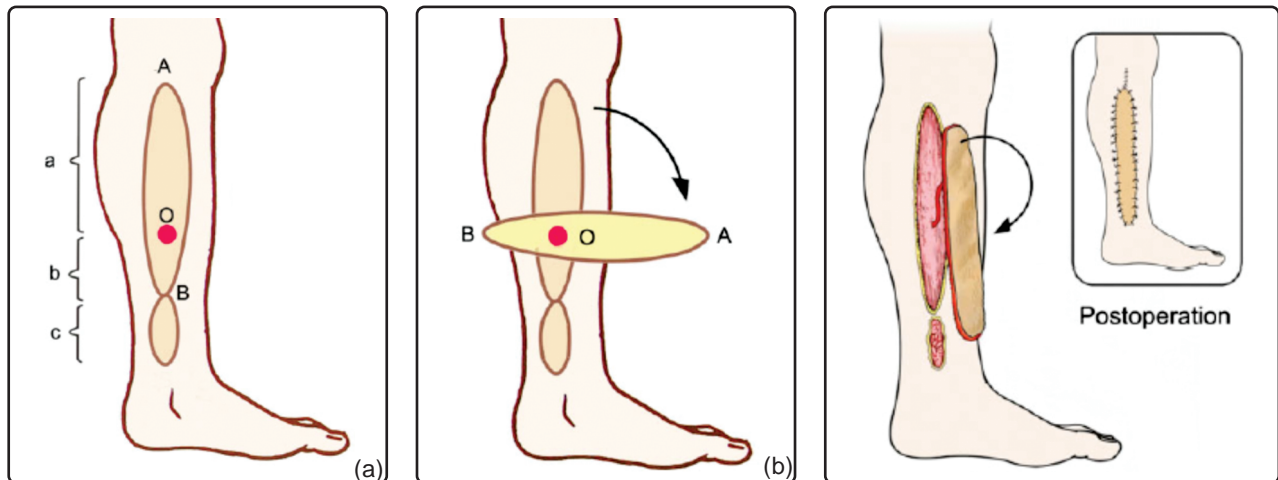


Fig. (1): Perforator pedicled propeller flap design [23].

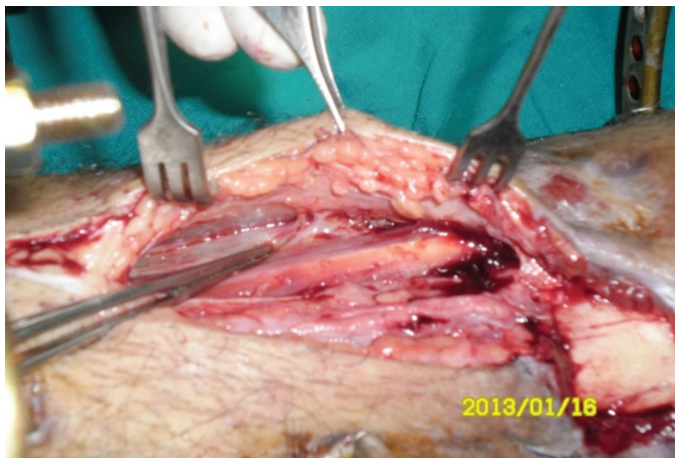

Fig. (2): Exposure of the perforator vessel.

RESULTS

A total of twenty seven patients with soft tissue loss underwent propeller flaps as a reconstructive procedure. Twenty three of them were males (85%) and four were females (15%). Their age range was 5-55 years (mean 32.11 ± 11.963 years). The most common cause was posttraumatic in fifteen patients (55.6%), followed by post burn contractures equals 25.9% of cases (Table 1). The most common site of reconstruction was distal leg and foot (Table 2) in fifteen patients (55.6%).

The mean Flap dimensions (Table 3) were 17.981 ± 5.4145 cm x 6.06 ± 2.233 cm (Length x width) with mean surface area of $120.463 \text{cm}^2 \pm 57.2414 \text{cm}^2$, range from (18-187 cm^2). The mean total operative time was 140.56 ± 30.801 minutes and the postoperative hospital stay was 16.04 ± 6.484 days. The donor site was closed primary in twelve cases (44.4%) while the majorities were required additional skin graft (fifteen cases (55.6%) of

cases). The flaps were thinned in four cases (14.8%) in form of removal of fascia and thin layer of fat in one blade of flap or major part of flap to decrease bulkiness and facilitate primary closure or closure without tension. Fourteen patients (51.9%) were underwent previous interventions in form of local advancement flaps and release of contractures and skin graft.

All patients tolerated the procedure without major risks. Twenty two cases were completely survived which represents 81.7% of all the flaps. There was no infection was reported.

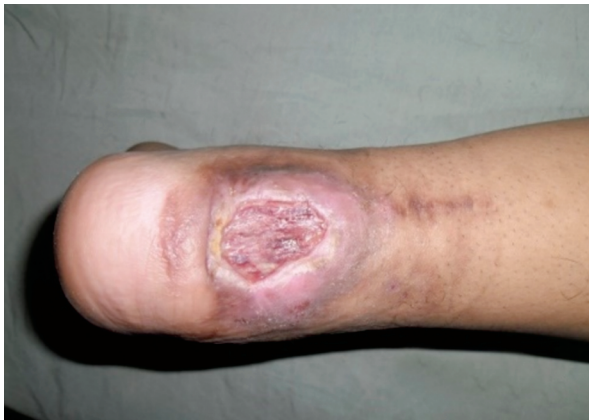Venous congestion was reported in seventeen patients (63%); distal third of twelve flaps and entire surface area of flap in five cases; complete resolution in eleven cases with conservative treatment by stitch removal and local subdermal heparinization. Total necrosis was occurred in three cases, two of them were diabetic and the third complicated by haematoma under the flap. The

remaining three cases were smokers and complicated by partial necrosis in two patients and epidermolysis in one flap.

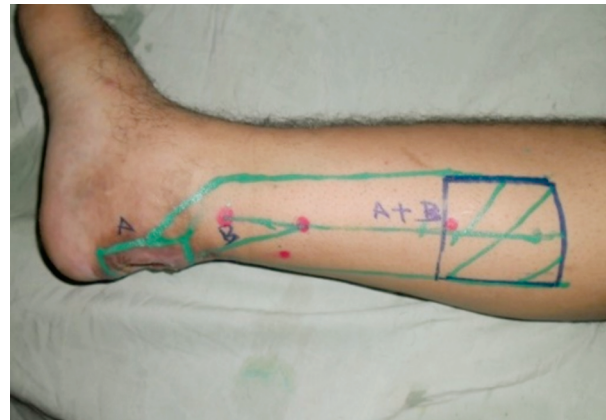
Other complications were occurred such as wound dehiscence in two cases (7.4%) and healed by secondary intension. Hypertrophic scar in donor site only of four cases and managed by conservative

therapy using local corticosteroid plus silicone sheet and pressure therapy.

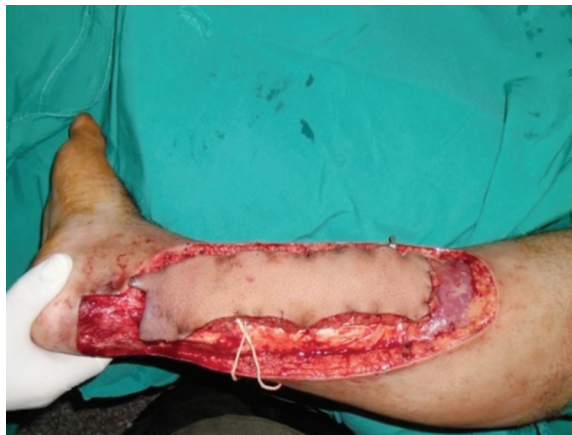All patients showed satisfactory results on discharge and on follow-up period (4 to 6 months). In addition, all patients were stable and good wound coverage without any morbidity related to procedure.



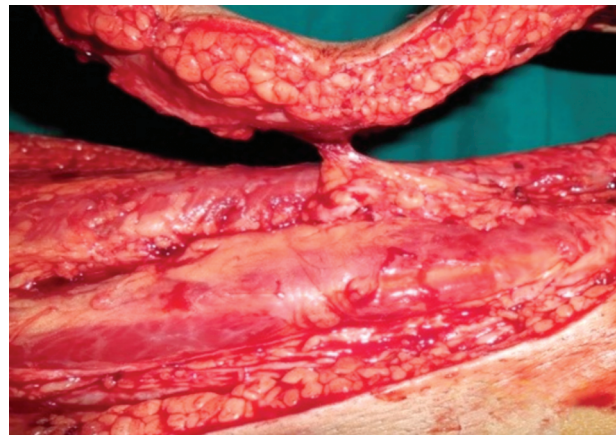
(A)



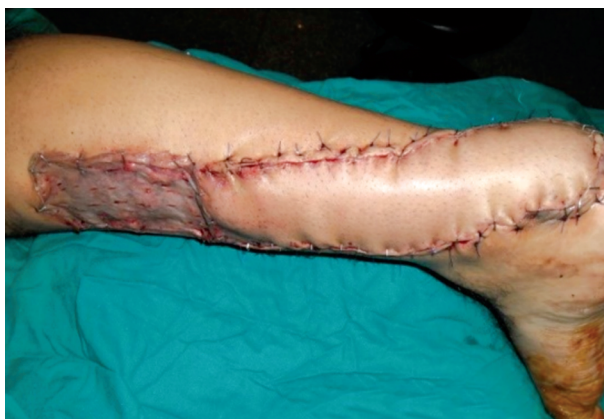(B)



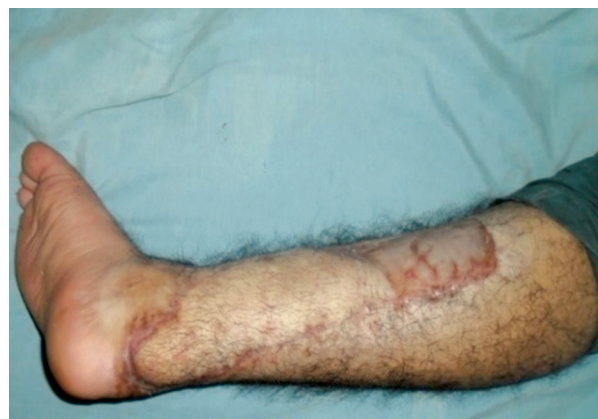(C)



(D)

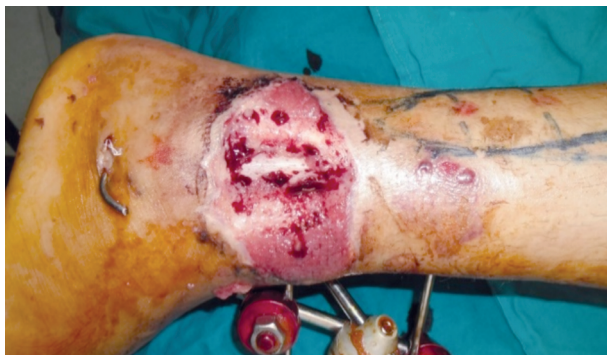

(E)

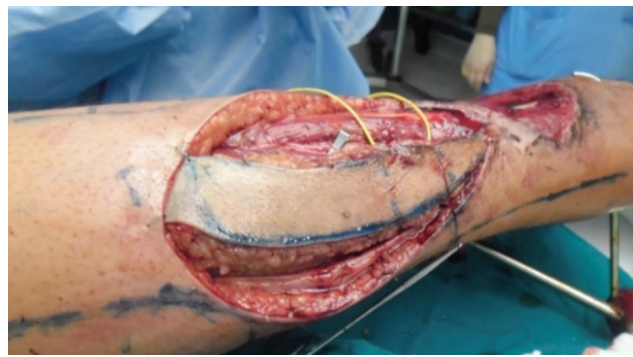

(F)

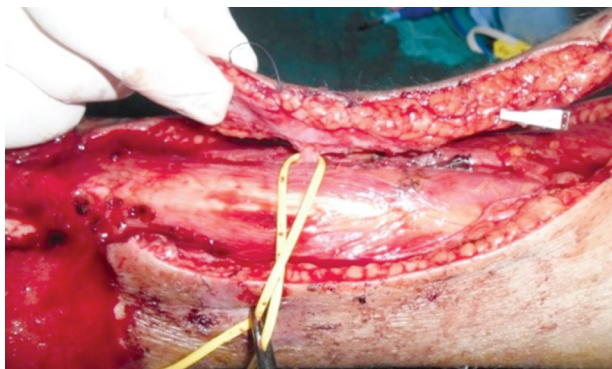
Fig. (3): (A) Male patient, 22 years old suffered from chronic ulcer over posterior aspect of heel, history of previous failed primary closure then conservative treatment for one year. (B) Location and marking of propeller flap on posterior tibial perforator. (C) Complete dissection of the flap. (D) Isolation of the Perforator vessel. (E) Rotation and inset of flap. (F) Late postoperative.



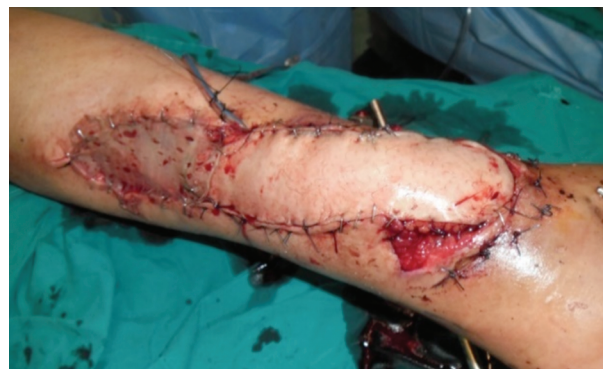(A)



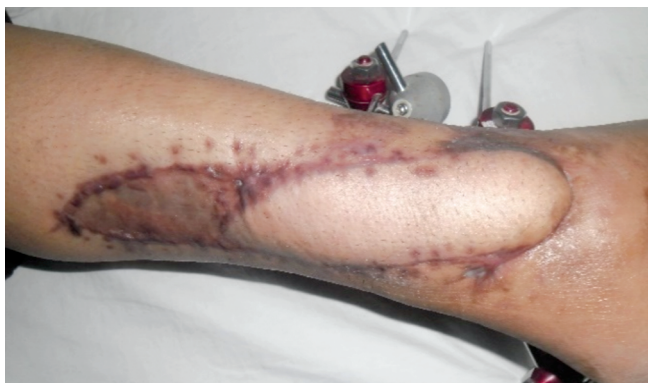(B)



(C)



(D)



(E)

Fig. (4): (A) Female patient, 25 years old with exposed lower fibula associated with fracture, location and marking of propeller flap from peroneal artery perforator. (B) Complete dissection of the flap. (C) Perforator. (D) Inset of flap. (E) Late postoperative.

Table (1): Etiology of the defects.

	Male	Female	Percent
Posttraumatic	14	1	55.6
Post burn injury	4	3	25.9
Bed ridden	3	0	11.1
Postoperative	2	0	7.4

Table (2): Location of defect.

Location of defect	Frequency	Percent
Heel and foot	8	29.6
Anterior leg region	7	25.9
Hand	4	14.8
Sacral area	3	11.1
Cubital fossa	2	7.4
Ischeal region	1	3.7
Popliteal fossa	1	3.7
Neck	1	3.7

Table (3): Flap dimensions, flap surface area, angle of rotation, donor site closure, flap thinning and their percentage and mean for all patients.

Case no	Flap dimension (cm)		Surface area cm ²	Angle of rotation (degrees)	Donor site closure	Flap thinning	Perforator source
	Length	Width					
1	24	7	168	180	S	No	PTAP
2	22	8.5	187	145	<i>p</i>	Yes	LUMBER <i>p</i>
3	20	5-7.5	185	90	<i>p</i>	No	SPP
4	18	6-7.5	175	90	<i>p</i>	No	SPP
5	12	5	60	180	S	No	PTAP
6	20	8.5	170	180	S	No	PAP
7	22	7	154	120	S	No	PAP
8	12	4	48	180	S	No	PTAP
9	27	4.5	121.5	180	<i>p</i>	Yes	PAP
10	16	7	112	180	S	No	PTAP
11	16	4.5	72	180	S	No	PTAP
12	16	10	160	180	S	No	SURAL
13	18	4.5	81	180	S	No	PAP
14	9	2	18	180	<i>p</i>	No	MCAP
15	24	5	120	180	<i>p</i>	Yes	PAP
16	7	1.5	10.5	180	<i>p</i>	No	MCAP
17	21	8	168	180	<i>p</i>	No	SGAP
18	18	8.5	153	180	S	No	PIN
19	19	6	114	160	S	No	PTAP
20	18	5	90	180	S	No	PTAP
21	19	7	133	180	<i>p</i>	No	IGAP
22	3.5	3.5	12.5	120	S	No	MTA
23	24	8	192	180	S	No	PAP
24	21	4	84	180	<i>p</i>	No	PIN
25	22	8.5	187	180	<i>p</i>	Yes	SGAP
26	19	8.5	178	180	<i>p</i>	No	SUPRA
27	18	5.5	99	180	S	No	PAP
Mean	17.98	6.06	120.463				
SD	5.414	2.233	57.2414				
Percent%	-	-	-	77.8% (180°)	S (55.6%) <i>p</i> (44.4%)	14.8%	

p : (Primary closure).

S : (Skin graft).

SPP : (Subcutaneous Pedicled Propeller Flap).

PTAP: (Posterior tibial artery perforator).

PAP : (Peroneal artery perforator).

IGAP: (Inferior gluteal artery perforator).

SGAP : (Superior gluteal artery perforator).

SUPRACLA: (Supraclavicular perforator).

MTA : (Metatarsal artery).

DMA : (Dorsal metacarpal artery).

PIN : (Posterior interosseous artery).

DISCUSSION

A variety of successful reconstructive procedures have been published in literature [8,17,20]. Propeller perforator flaps are best suited for small and medium defects and in trauma patients for defects without extensive avulsion and degloving injuries [6,10].

The use of propeller flaps has increased over the last decade due to several advantages due to minimal donor site morbidity, relatively simple surgical technique, and reconstruction of tissue using "like-by-like" principles [5,11].

In study of Masia, et al., [12] reported incidence of partial necrosis occurred in three propeller flaps

(5%) in heavy smoker patients and (1%) in a diabetic patient. The propeller flaps survival can be explained on adequate perfusion through perforators that rich suprafascial and subfascial plexus at level of deep fascia with adjacent perforators. The vascular connections between the angiosomes showed them to be inadequate to nourish the distal part of the flap, probably due to the microvascular damage caused by smoke and diabetes. In the current study, vascular insufficiency was observed in 6 cases in the form of epidermolysis, partial necrosis and complete necrosis a smoker and diabetic patients, this is in accordance with the previous result.

Multidetector-row computed tomography angiography (MDCTA) [14,15] or computed tomogra-

phy angiography (CTA) was adopted to accurate identification of the perforator [16]. In addition, the superiority of MDCTA over the other less invasive imaging techniques should be presumed even if comparative studies are required, because it allows for determining a more precise location of the perforator and its subcutaneous course through three dimensional reconstruction imaging [15]. In this study, the location of the best perforator closest to the defect has been detected preoperatively with a handheld Doppler in almost all cases with accuracy 100%.

Authors preferred subfascial dissection under loupe magnification to identify all the perforators around the defect because this plane of dissection is faster and the perforator is more clearly localized and freed. Also, if the skin part of the flap is lost, the fascia may still be intact and graftable.

There is no big difference in flap survival between the fasciocutaneous and adipocutaneous propeller flaps. On the other hand, suprafascial dissection leaves a less consistent donor site defect and makes flap dissection easier at the sites where the muscular septa join the muscular fascia. This our preferable agree with other reports in the literature [12,13,17,18].

Topalan et al., [24] and Bilgin et al., [25] demonstrated that one week after performing the pedicle torsion, the microvascular patency rate is 100% with torsions of 90 and 180 degrees for arteries and veins respectively. In reality, there is a critical phase during 72 hours. If torsion more than 90 degrees, the thrombotic risk is high for veins and used anticoagulant in postoperative period. After this delay, the microvascular patency rate returns at a normal level, and the risk of venous thrombosis is almost non-existent. In this way, we used a preventive anticoagulation in form of enoxaparin sodium and aspirin during first 72 hours for propeller flaps in fifteen cases.

To our knowledge, there was not enough data in literature based on clinical series analyze the effect of arc of rotation on complications. In this work, rotation angle was range from 90 degrees to 180 degrees. The flaps were rotated 180 degrees in twenty one flaps (77.8%). Our observation is increased risk of venous congestion increased with increase arc of rotation.

In current study, venous congestion was the most common complication. Other reports established that venous congestion was the most common complication because veins are more prone to

torsion than arteries [2,11,13]. True venous insufficiency worsens with time and should be promptly recognized and treated. When it is limited to an apical part of the flap, its evolution is observed. A small number of cases evolve in necrosis, which is usually superficial, so that deep vital tissue is still present at the recipient site [2,11,20]. Neovascularization produces new paths for the relief of congestion approximately 4 to 10 days after surgery. Without treatment, congested tissue becomes ischemic and if ischemia is severe, tissue necrosis can occur [21,22].

However in this study, there was highest reported venous congestion, but affecting distal part of flap in twelve patients. Venous congestion was resolved in eleven cases, epidermolysis was reported in one flap, partial necrosis in two flaps and complete necrosis in other three cases representing failure rate of 11.4% but it leave granulation tissue in the bed which was managed by skin graft. Another flap was done in two cases because they in need for bone graft. The overall flap loss in flaps used for leg reconstruction which is closely similar to the reported failure rate of free flaps (4% to 19%) [18]. Also, closely similar to failure rate in study of Panse, et al., [19] and Tos et al., [11] (12%, 13% respectively).

Authors can't deny that the donor site morbidity is evident but it is well compensated and satisfied from all patients.

In this study, several advantages are observed, they includes; simple design, safe without scarification of axial vessels or nerves or muscles at donor site, easy technique, reliable to cover the defects due to its extensive arc of rotation and single stage without microsurgery, limiting the donor site to the same area, possibility of completely or partially primarily closure.

Moreover, propeller flap have an advantage over free flap. If a free flap is lost, everything is lost, but if the superficial part of propeller flap is lost, the flap did its job of covering the exposed anatomical elements.

Conclusion:

Authors have advised that Propeller flaps are safe and reliable flaps and one of the ideal option for reconstruction of soft tissue defects. Whenever possible, surgical intervention and donor site morbidity were limited to a single body region and the use of propeller perforator flaps can widen the reconstructive options for inferior limb defects.

REFERENCES

- 1- Wei F.C., Jain V., Suominen S. and Chen H.C.: Confusion among perforator flaps: What is a true perforator flap? *Plast. Reconstr. Surg.*, 107 (3): 874-876, 2001.
- 2- Pignatti. M., Koshima I., Ogawa R., Ono S., Hyakusoku H., Georgescu A., Hallock G.G.: The "Tokyo" Consensus on Propeller Flaps. *Plast. Reconstr. Surg.*, 127 (2): 716-721, 2011.
- 3- Hallock G.G.: Lower extremity muscle perforator flaps for lower extremity reconstruction. *Plast. Reconstr. Surg.*, 114 (5): 1123-1130, 2004.
- 4- Hyakusoku H., Yamamoto Y. and Fumiiri M.: The propeller flap method. *Br. J. Plast. Surg.*, 44: 53-54, 1991.
- 5- Jakubietz R.G., Schmidt K., Zahn R.K., Waschke J., Zeplin P.H., Meffert R.H. and Jakubietz M.G: Subfascial Directionality of Perforators of the Distal Lower Extremity. "An Anatomic Study Regarding Selection of Perforators for 180-Degree Propeller Flaps" *Ann. Plas. Surg.*, 69 (3): 307-311, 2012.
- 6- Jakubietz R.G., Jakubietz M.G., Gruenert J.G. and Kloss D.F.: The 180 degree perforator based propeller flap for soft tissue coverage of the distal lower extremity: A new method to achieve reliable coverage of the distal lower extremity with local fasciocutaneous perforator flap. *Ann. Plast. Surg.*, 59 (6): 667-671, 2007.
- 7- Hallock G.G.: The propeller flap version of the adductor Muscle perforator flap for coverage of ischial or trochanteric pressure sores. *Ann. Plast. Surg.*, 56 (5): 540-542, 2006.
- 8- Ayestary B., Ogawa R., Ono S. and Hyakusoku H.: Propeller flaps: Classification and clinical applications. *Annales de chirurgie plastique esthétique*, 56: 90-98, 2011.
- 9- Teo T.C.: Perforator local flaps in lower limb reconstruction. *Cir. Plast. Ibero-Latinoam.*, 32: 15-16, 2006.
- 10- Quaba O. and Quaba A.A.: Pedicled perforator flaps for the lower limb. *Semin. Plast. Surg.*, 20: 103-111, 2006.
- 11- Tos P., Innocenti M., Artiaco S., Antonini A., Delcroix L., Geuna S. and Battiston B.: Perforator based propeller flaps treating loss of substance in the lower limb, *Orthopaed Traumatology*, 12: 93-99, 2011.
- 12- Masia J., Moscatiello F., Pons G., Fernandez M., Lopez S. and Serret P.: Our experience in lower limb reconstruction with perforator flaps, *Ann. Plast. Surg.*, 58 (5): 507-512, 2007.
- 13- Lazzeri D., Huemer G.M., Nicoli F., Larcher L., Dashti T., Grassetti L., Li Q., Zhang Y., Spinelli G. and Agostini T.: Indications, outcomes and complications of pedicled propeller perforator flaps for upper body defects: A Systematic review. *Arch. Plast. Surg.*, 40 (1): 44-50, 2013
- 14- Ono S., Chung K.C., Hayashi H., Ogawa R., Takami Y. and Hyakusoku H.: Application of multidetector row computed tomography in propeller flap planning. *Plast. Reconstr. Surg.*, 127: 703-711, 2011.
- 15- Ono S., Sebastin S.J., Yazaki N., Hyakusoku H. and Chung K.C.: Clinical applications of perforator based propeller flaps in upper limb soft tissue reconstruction. *J. Hand Surg. Am.*, 36: 853-863, 2011.
- 16- Higuera Sune M.C., Lopez O.A., Narvaez Garcia J.A., De Albert De Las Vigo M., Roca Mas O., Perez Sidelnikova D., Carrasco López C., Palacin Porte J.A., Serra Payró J.M. and Viñals J.M.: Use of angioscanning in the surgical planning of perforator flaps in the lower extremities. *J. Plast. Reconstr. Aesthet. Surg.*, 64 (9): 1207-1213, 2011.
- 17- Pignatti M., Pasqualini M., Governa M., Massimiliano B. and Rigott G.: Propeller flaps for leg reconstruction. *Plastic, Reconstructive and Aesthetic Surgery*, 61: 777-783, 2008.
- 18- Gir P., Cheng A., Oni G., Mojallal A. and Saint-Cyr M.: Pedicled-perforator (propeller) flaps in lower extremity defects: A Systematic review. *J. Reconstr. Microsurg*, 28 (9): 595-602, 2012.
- 19- Panse N. and Sahasrabudhe P.: Free style perforator based propeller flaps: Simple solutions for upper extremity reconstruction. *Indian journal of plastic surgery*, 47 (1): 77-84, 2014.
- 20- Alexandru V. Georgescu: Propeller Perforator Flaps in Distal Lower Leg: Evolution and Clinical Applications. *Arch. Plast. Surg.*, 39 (2): 94-105, 2012.
- 21- Pérez M., Sancho J., Ferrer C., García O. and Barret J.P.: Management of flap venous congestion: The role of heparin local subcutaneous injection. *J. Plast. Reconstr. Aesthet. Surg.*, 67 (1): 48-55, 2014.
- 22- Iglesias M., Butroń P.: Local subcutaneous heparin as treatment for venous insufficiency in replanted digits. *Brit. J. Plast. Surg.*, 103 (6): 1719-1724, 1999.
- 23- Dong K.X., Xu Y.Q., Fan X.Y., Xu L.J., Su X.X., Long H., Li-Xu Q. and He X.Q.: Perforator Pedicled Propeller Flaps for soft tissue coverage of lower leg and foot defects. *Orthopaedic Surgery*, 6 (1): 42-46, 2014.
- 24- Topalan M., Bilgin S.S., Ip W.Y. and Chow S.P.: Effect of torsion on microarterial anastomosis patency. *Microsurgery*, 23 (1): 56-59, 2003.
- 25- Bilgin S.S., Topalan M., Ip W.Y. and Chow S.P.: Effects of torsion on microvenous anastomotic patency in a rat model and early thrombolytic phenomenon. *Microsurgery*, 23 (4): 381-386, 2003.